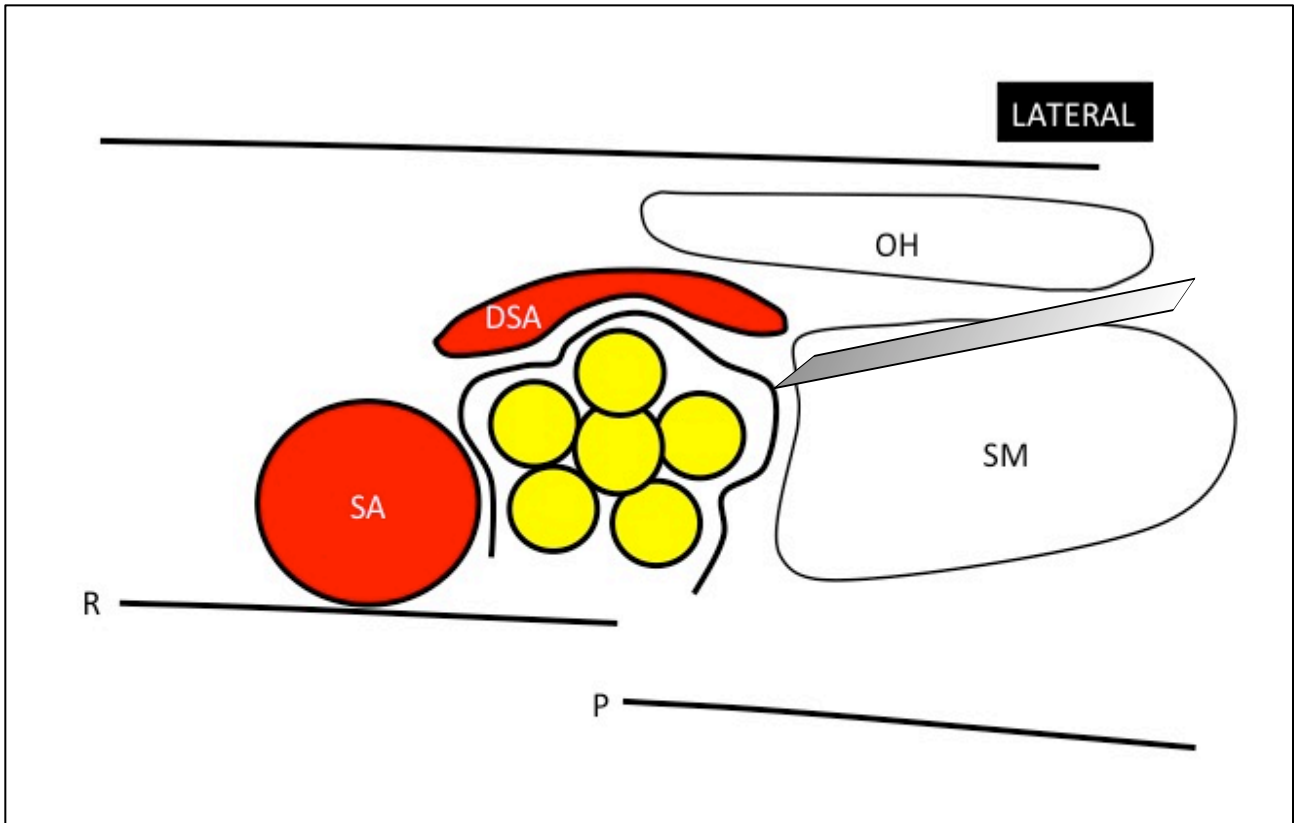


# SUPRACLAVICULAR

D. Wong  
M. Barrington

*Toolbox:* online module 8, RAP lecture 3, 23; hands-on module 3



Ensure needle tip is imaged and superficial to the 1<sup>st</sup> rib (R). The brachial plexus above the rib is of variable depth and the needle trajectory may be challenging. Identify the pleura (P) slightly deep to the 1<sup>st</sup> rib. The transducer position and orientation influences the sonogram, for example, the relationship of plexus, subclavian artery (SA), first rib and muscles. The brachial plexus divisions (yellow structures) are deep to the prevertebral fascia. This region is vascular (e.g. dorsal scapular artery (DSA). Scalenus medius, (SM) and the omohyoid (OH).

## KEY STRUCTURES

- SCALENUS MEDIUS
- OMOHYOID
- PREVERTEBRAL FASCIA
- DORSAL SCAPULAR ARTERY
- SUBCLAVIAN ARTERY
- BRACHIAL PLEXUS (DIVISIONS)
- FIRST RIB
- PLEURA

## INDICATIONS

- Mid-distal humeral fractures
- Major elbow surgery
- Major forearm surgery (e.g. ORIF radius)\*
- Wrist arthrodesis/arthroscopy\*
- Carpal, metacarpal ORIF\*#
- Arterio-Venous access

*\*Axillary approach also effective*

*#Suggest axillary approach if surgery in ulnar nerve distribution*

## CONTRAINDICATIONS

- Contralateral recurrent laryngeal or phrenic nerve paresis
- Contralateral pneumonectomy or pneumothorax
- Reduced pulmonary reserve (relative contraindication)

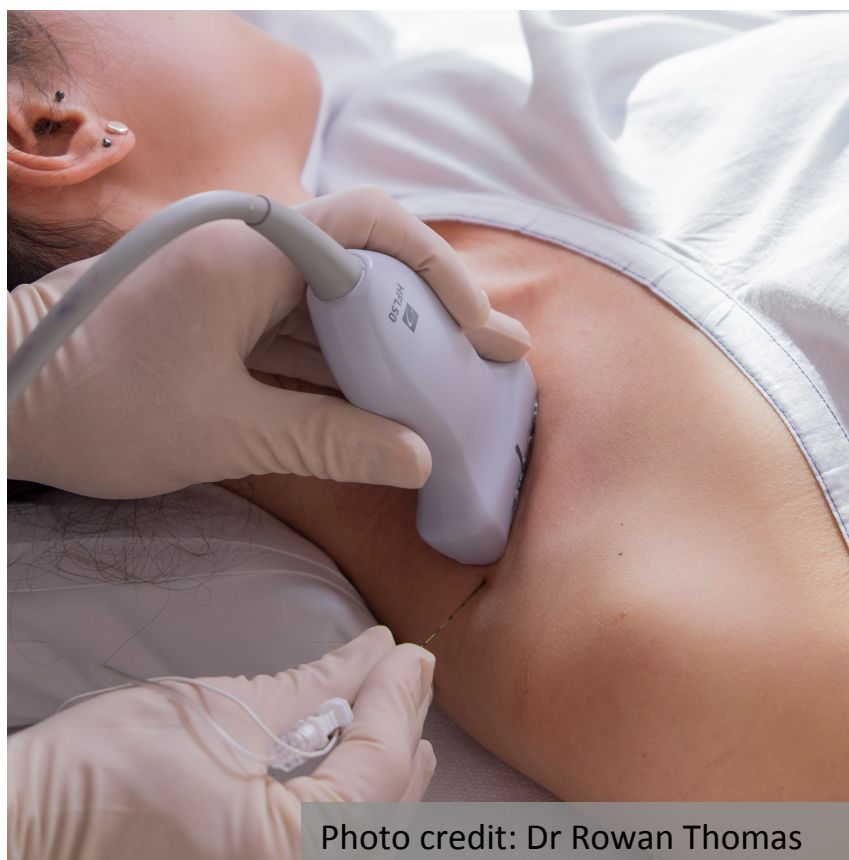
## SUGGESTED LOCAL ANESTHETIC DOSAGES

- Surgical anesthesia and analgesia: 20 – 30 mL 0.5 - 0.75% ropivacaine
- Surgical anesthesia: 20 – 30 mL 1.5 - 2% lignocaine + epinephrine 1:200,000 or mepivacaine 1.5 – 2% (e.g. reno-vascular access)
- Postoperative analgesia alone: 20 – 30 mL 0.2 – 0.5% ropivacaine

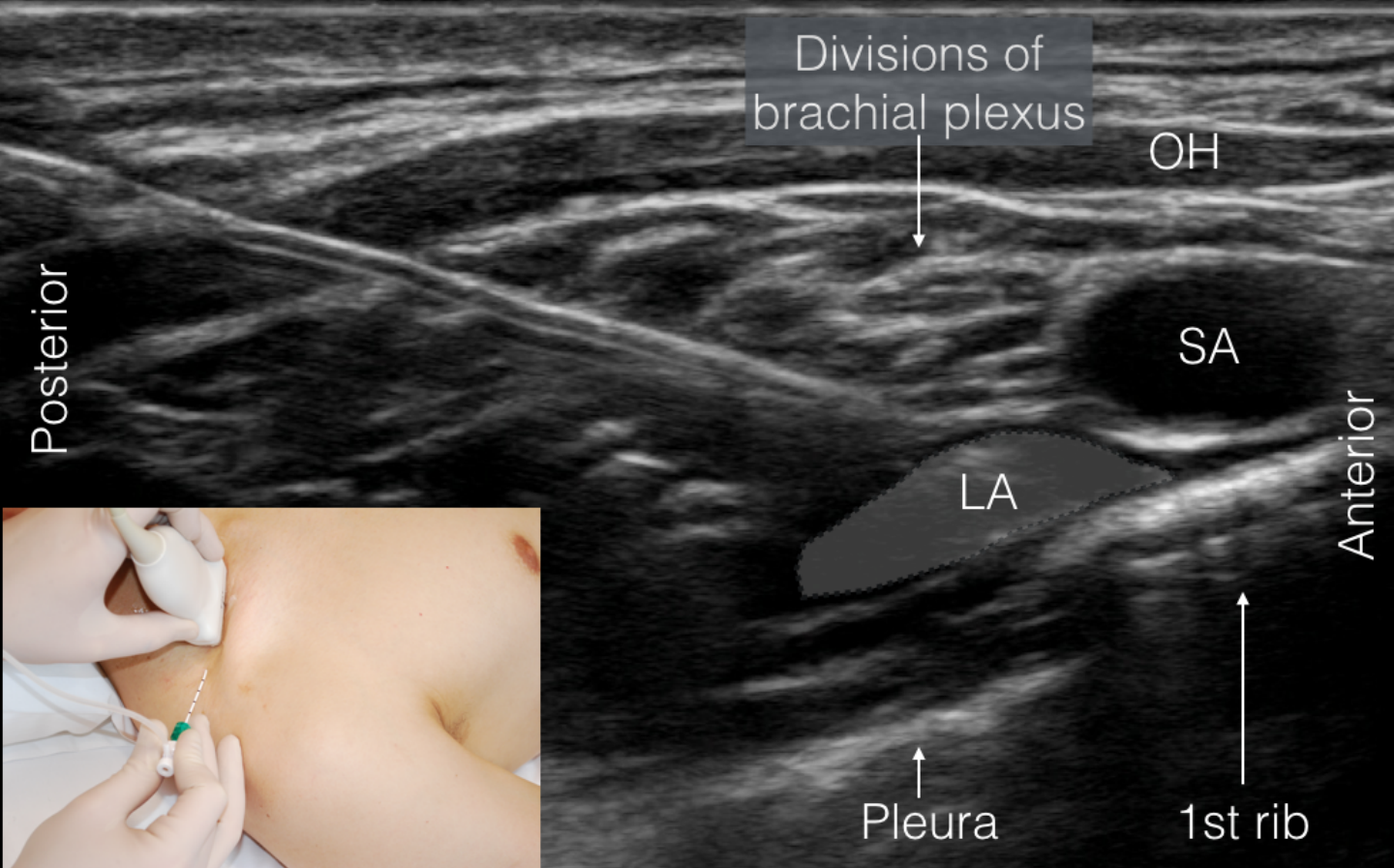
## TRANSDUCER

- High to intermediate frequency linear transducer: bandwidth 10 - 15 MHz, width: 25 – 50 mm

**NEEDLE** 50 – 100 mm



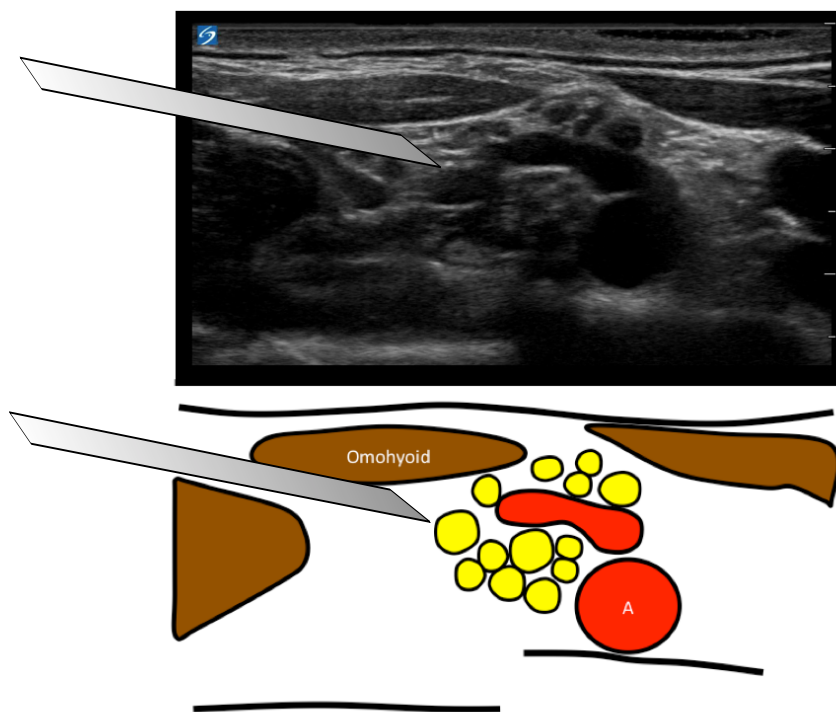
Note: the above linear transducer has a width of 50 mm, this may necessitate the use of a longer needle compared to use of a transducer with a smaller footprint, for example, 25 mm width



Sonogram adapted from Gray et al, 3<sup>rd</sup> ed. Atlas of Ultrasound-Guided Regional Anesthesia

OH = omohyoid muscle; SA, subclavian artery; LA, local anesthetic injectate  
'lifting' plexus up

Vascularity -the dorsal scapular artery is frequently imaged. Suggest imaging the planned needle trajectory using colour Doppler mode



# A few strategies for needle imaging and controlling spread of local anaesthetic.

Refer to online modules 3 – 4, hands-on module 1

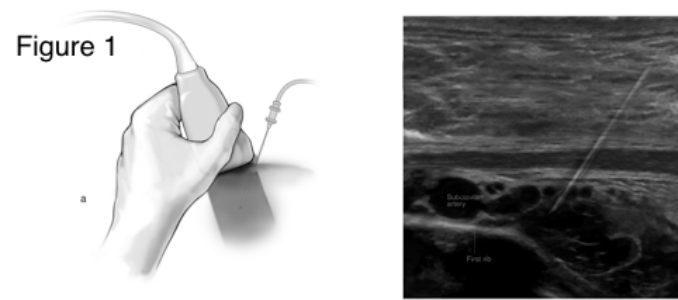


Figure 1. Separating needle from transducer may help with needle trajectory and needle imaging

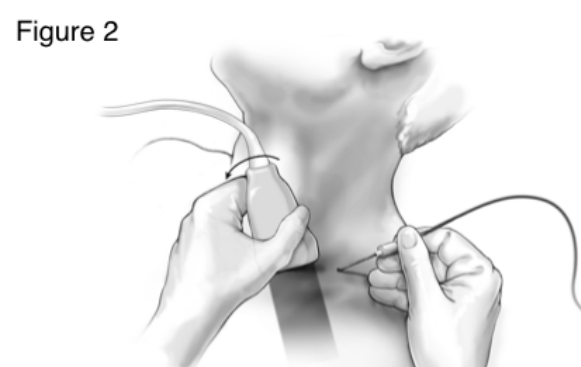
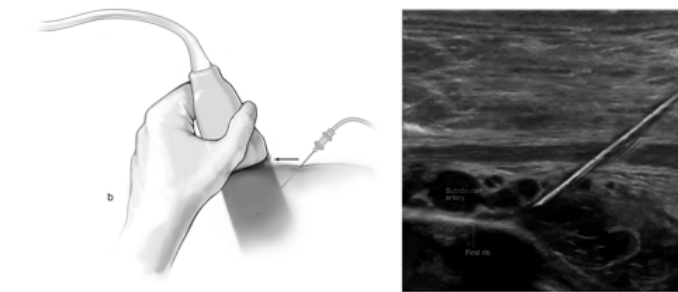


Figure 2. Rocking transducer in its long-axis away from needle may improve needle imaging

# A few strategies for needle imaging and controlling spread of local anaesthetic.

## Refer to online modules 3 – 4, hands-on module 1

Figure 3. Using a step-down approach may help, with initial shallow trajectory it should be easier to image the needle, then needle is maintained in-plane as trajectory becomes steeper

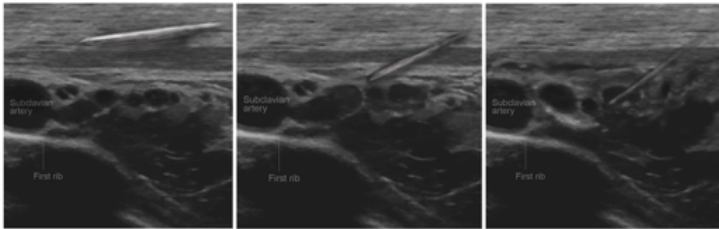


Figure 5. Hydrodissection can improve image quality of both needle and neural targets

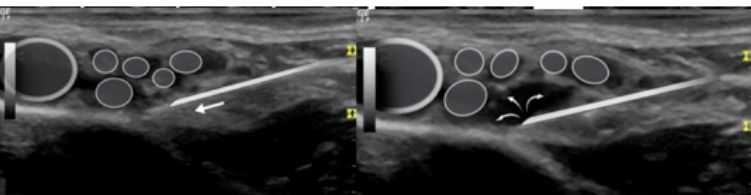

Figure 4. The fascial planes can control spread of injectate, that is, the needle tip does not need to be where the injectate spread is intended

